



CASE REPORT

Patient with Severe Skeletal Class II Malocclusion: Double Jaw Surgery with Multipiece Le Fort I

Merve Altay Burgaz¹ , Feyza Eraydın² , Simge Diren Esener³ , Ersin Ülkür⁴ 

¹Department of Orthodontics, Altınbaş University School of Dentistry, İstanbul, Turkey

²Department of Orthodontics, Yeditepe University School of Dentistry, İstanbul, Turkey

³Private Practice of Orthodontics, İstanbul, Turkey

⁴Private Practice of Plastic and Reconstructive Surgery, İstanbul, Turkey

ORCID IDs of the authors: M.A.B. 0000-0002-6934-8561; F.A.0000-0002-7791-6979; S.D.E. 0000-0001-5862-7461; E.Ü. 0000-0003-4946-903X.

Cite this article as: Altay Burgaz M, Eraydın F, Diren Esener S, Ülkür E. Patient with Severe Skeletal Class II Malocclusion: Double Jaw Surgery with Multipiece Le Fort I. Turk J Orthod 2018; DOI: 10.5152/TurkJOrthod.2018.17039

ABSTRACT

A 22-year-old woman with severe skeletal Class II malocclusion was referred to our clinic. A clinical examination revealed a convex soft tissue profile and increased teeth and gingiva exposure both while smiling and in the natural rest position. She had Class II molar and canine relationship with increased overjet, moderate crowding in both upper and lower jaws, and proclined upper and lower incisors. Skeletally, she showed transverse maxillary deficiency, maxillary vertical excess, and mandibular retrognathia. We planned orthodontic-orthognathic surgery with multipiece Le Fort I osteotomy and bilateral sagittal split osteotomy (BSSO) to achieve ideal occlusion, stability, and facial esthetics. During orthodontic decompensation to relieve the crowding and to gain an ideal incisor inclination, four bicuspid extractions were performed. Because we used continuous mechanics, at the end of the decompensation period, we cut the maxillary arch wire distal to the lateral incisors into three pieces and waited for 3 months for vertical and transversal dental relapse. During the double jaw surgical procedure, the maxilla expanded and impacted with multisegmented Le Fort I osteotomy and the mandible advanced with BSSO. After the orthodontic and orthognathic surgical treatment, the skeletal and dental imbalance was corrected, and functional occlusion and dental and skeletal Class I relationship were achieved. The treatment results were stable at the 1-year follow-up.

Keywords: Orthognathic surgery, skeletal Class II, multipiece Le Fort I

INTRODUCTION

In skeletal Class II patients, treatment alternatives vary according to the skeletal maturity level, severity of the malocclusion, facial appearance, and patient's expectations and cooperation (1-4). In growing patients, growth modification treatments either with removable or fixed functional applications, in which patient cooperation is the primary concern, are preferred (2-7). In adult patients, camouflage orthodontic treatment can be an option when there are mild-to-moderate anteroposterior (A-P) skeletal discrepancies with acceptable vertical facial proportions and no transverse skeletal problems (8-10). Camouflage treatment is mainly based on the retraction of the upper incisors by extracting the upper first premolars or whole maxillary arch distalization using temporary anchorage devices and protraction of the lower incisors to resolve increased overjet (8-14). In some instances, extractions of the mandibular second premolars are also performed for obtaining a Class I molar relationship by lower molar mesialization. However, this treatment is limited by tooth movements for compensating the underlying skeletal discrepancies (3). In severe cases, camouflage treatment means that fitting teeth on improper skeletal bases can lead to possible periodontal problems, such as gingival recession in the lower anterior region, root resorptions, worsening of facial esthetics, and occlusal instability (3, 4, 8-10). Therefore, in patients with

Address for Correspondence: Merve Altay Burgaz, Department of Orthodontics, Altınbaş University School of Dentistry, İstanbul, Turkey E-mail: mrvalty@hotmail.com

©Copyright 2018 by Turkish Orthodontic Society - Available online at www.turkjorthod.org

Received: 23 August 2017

Accepted: 1 March 2018

Available Online Date: 11 July 2018

severe A-P skeletal discrepancies, transverse maxillary skeletal constriction, airway problems, and improper facial esthetics, orthognathic surgery combined with orthodontic treatment is the best treatment alternative to gain ideal results regarding function, esthetics, and stability (4, 8-10, 12-18). During the presurgical orthodontic treatment, dental decompensation by moving teeth to a proper position relative the skeletal bases, which is just the opposite of the camouflage treatment, is performed (3, 4). During this phase of treatment, the aim is to remove dental interferences for the ideal correction of existing skeletal discrepancies. This case report describes the orthodontic-orthognathic surgery treatment in a 22-year-old woman with skeletal Class II malocclusion due to mandibular retrognathia.

CASE PRESENTATION

A 22-year-old woman with a complaint of mandibular retrognathia was referred to our clinic. Extraorally, she had a convex soft tissue profile and increased teeth and gingiva exposure both while smiling and in the natural rest position. Intraorally, she had the Class II molar and canine relationship and 10-mm overjet and 4-mm overbite. There was 6-mm crowding in the upper jaw and 7-mm crowding in the lower jaw. The upper midline was coincident with the face, whereas the lower midline was 2.5 mm deviated to the right. Transversally, a 4-mm maxillary con-

striction existed between the lower and the upper first premolars (Figure 1).

Skeletally, the patient had Class II malocclusion (ANB, 8°) due to mandibular retrognathia (SNB, 71.8°). The maxillary depth angle was increased (63.5°), indicating a vertically overdeveloped maxilla. Both upper and lower incisors were proclined with an angle of I-SN 112.2° and IMPA 101° (Table 1). The third molars were present (Figure 2).

Treatment objectives were the following: (1) relieving dental crowding and gaining an ideal dental arch alignment; (2) obtaining Class I dental and skeletal relationship with an ideal functional occlusion; (3) fitting maxilla and mandible transversally by maxillary expansion; (4) gaining ideal teeth and gingival exposure; and (5) improving facial esthetics. To achieve these objectives, an orthodontic-orthognathic combined treatment was planned.

For this patient, in the field of the orthodontic and orthognathic surgery approach, there were two treatment options, namely surgically-assisted rapid palatal expansion followed by fixed orthodontic treatment and final double jaw orthognathic surgery or orthodontic decompensation followed by double jaw surgery with multipiece Le Fort I osteotomy. Our patient's maxillary constriction was in the physiological limits of the multipiece Le Fort I

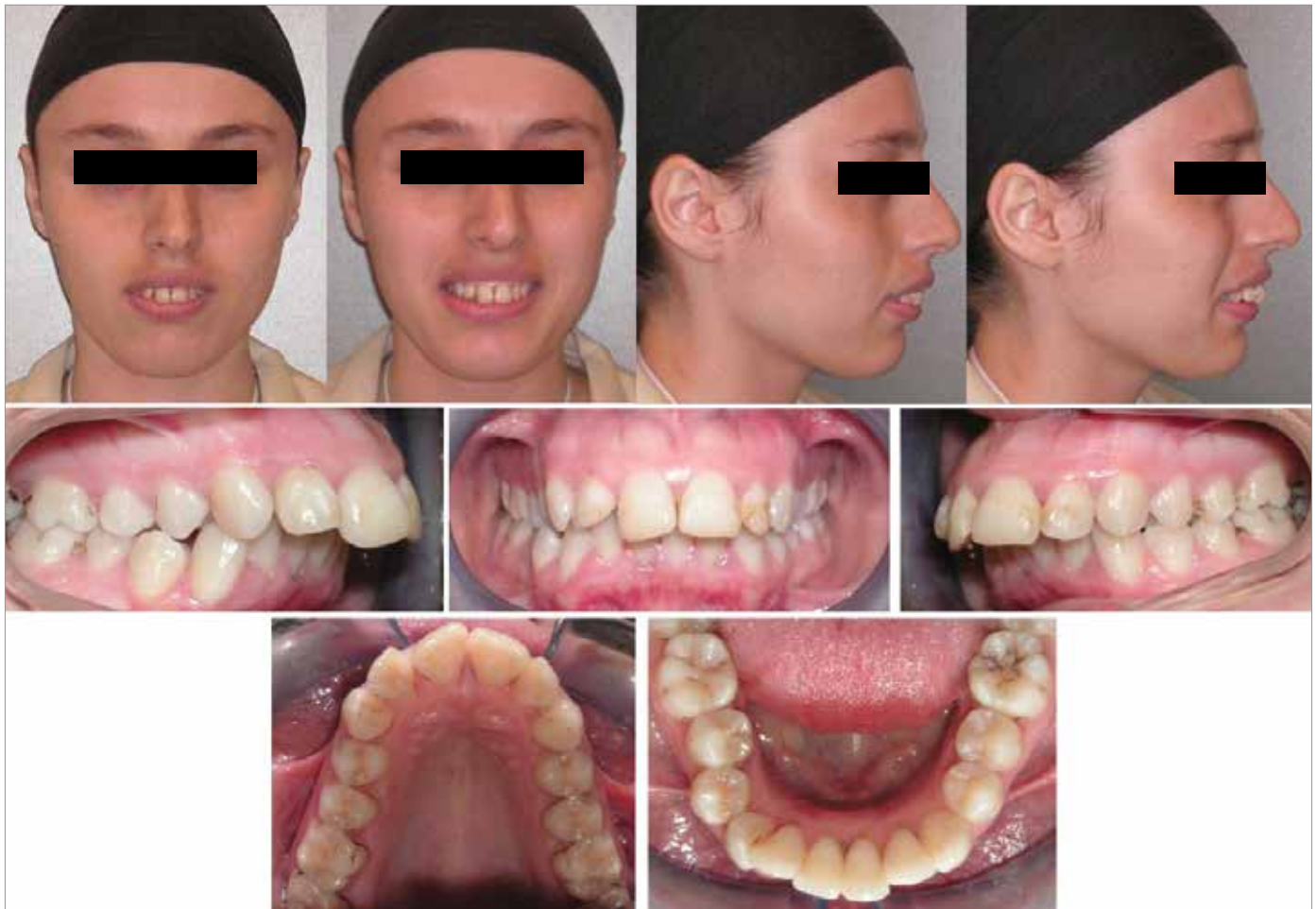

Figure 1. Pretreatment extra- and intraoral photographs

Table 1. Lateral Cephalometric Measurements

Cephalometric Measurement	Mean	Initial	Preoperative	Postoperative	1 Year After Treatment
VERTICAL ANALYSIS					
SN-GoGn	32°±8°	38.1°	37°	39°	39°
Saddle angle	123°±5°	137.6°	134.5°	139°	139°
Articular angle	143°±6°	144.2°	148°	136°	136°
Gonial angle	130°±7°	112.5°	110°	120.6°	120°
Sum of interior angles	396°±3°	394.3°	392.5°	395.6°	395°
Jarabak (SGo-NMe)	59%-63%	63.5%	64.6%	59%	60.8%
ANS-Me/N-Me	55%	58.4%	59.8%	61%	61.1%
Max. height angle	60°	63.5°	62°	58.5°	58.4°
Facial axis angle	90°	85.4°	85.6°	91°	91°
S-Ar/Ar-G (ramus)	75%	76.6%	72%	79%	80%
Gonial ratio	75%	59%	56%	66%	66%
FMA	25°	28.6°	29.4°	28.8°	28.5°
Y-axis angle	59.4°	76.5°	76.6°	72.7°	72.7°
OkI. plane/SN	14°	15.5°	20°	16.8°	15.8°
OkI. plane/Mand. plane	18°	24.2°	18.9°	24.4°	23.4°
SAGITAL ANALYSIS					
SNA	82°±2°	79.8°	80.2°	81.5°	81.5°
SNB	80°±2°	71.8°	71.4°	76°	75.8°
ANB	2°	8°	8.8°	5.5°	5.7°
Witt's	-1 mm	9.9 mm	8.1 mm	3.9 mm	4.5 mm
Ant. cran. base	73 mm	62 mm	62 mm	62 mm	62 mm
Mand. corpus length	80 mm	80.4 mm	80 mm	88 mm	88 mm
Postcranial base	37 mm	33.3 mm	33.3 mm	33.3 mm	33.3 mm
N-A per	-1 mm	-3.4 mm	-2.4 mm	-1.4 mm	-1.4 mm
Max. depth	90°	91.2°	90.4°	93°	94°
SL	51 mm	30.4 mm	30.5 mm	39.2 mm	39.2 mm
SE	22 mm	24.6 mm	22.8 mm	24.7 mm	24.7 mm
DENTAL ANALYSIS					
U1-SN	103°	112.2°	104°	98°	96°
U1-FH	112°	124.2°	114°	110°	108°
U1-Pal. plane	115°	123.3°	111.5°	104°	103°
U1-NA	22°	33°	23.4°	17°	16°
U1-NA	4 mm	8 mm	2.2 mm	1 mm	0.8 mm
IMPA	90°	101°	92.3°	85.4°	85.6°
L1-NB	25°	33.4°	22.9°	22.4°	22.7°
L1-NB	4 mm	8.5 mm	3 mm	5 mm	5 mm
Pog-NB	4 mm	4 mm	4.7 mm	5.5 mm	5.5 mm
Holdaway ratio	1/1	0.5	1.6	1.1	1.1
Interincisal angle	131°	105.6°	124.6°	136°	137.8°
SOFT TISSUE ANALYSIS					
Nasolabial angle	102° ± 8°	108.9°	117.9°	119°	117°
Holdaway angle	8°	16.7°	13.8°	7.5°	7°
Upper lip-E line	-4 mm	-1.6 mm	-3.2 mm	-6 mm	-6.4 mm
Lower lip-E line	-2 mm	0.4 mm	-0.6 mm	-3.5 mm	-3.6 mm
Soft tissue convexity	168°±4°	123.4°	121.6°	126.3°	125.4°

procedure; therefore, to avoid possible complications of the second surgery, we preferred maxillary expansion and repositioning with a multipiece surgical intervention.

Before starting the orthodontic treatment, a written informed consent was obtained from the patient. Following, the patient's third molars and upper and lower first premolars were extracted. All first and second molars were banded, and the remaining

teeth were bonded with 0.022-in Roth metal braces. After leveling the dental arches, extraction spaces were closed by sliding mechanics to gain an ideal incisor inclination according to our cephalometric surgical prediction tracing (Figure 3-5). Because we worked with continuous mechanics, to be able to see the real skeletal problem, dental relapse in all dimensions (transversal, sagittal, and vertical) was needed. A 0.019 × 0.025-in stainless steel upper archwire was segmented into three pieces from distal to the lateral incisors (Figure 3). We waited for approximately 3 months for a possible dental relapse. After the decompensation period, orthognathic surgery, which involved maxillary multipiece Le Fort I osteotomy and mandibular bilateral sagittal split osteotomy, was performed. Virtual treatment planning was done using software (Dolphin Imaging and Management Solutions Chatsworth, California). The maxilla was expanded with segmental osteotomy, and the upper incisor tip moved 2.3 mm forward and 3 mm upward, whereas the lower incisor tip moved 11 mm forward, and mandibular counter-clockwise rotation was performed (Figure 6).

To avoid early postoperative relapse, we bonded the segmented maxillary archwire with light-cure flowable composite during the surgery. Titanium plates were used for rigid fixation. A 10-day inter-maxillary fixation (IMF) was postoperatively performed. To prevent relapse, the final splint was left attached to the maxillary

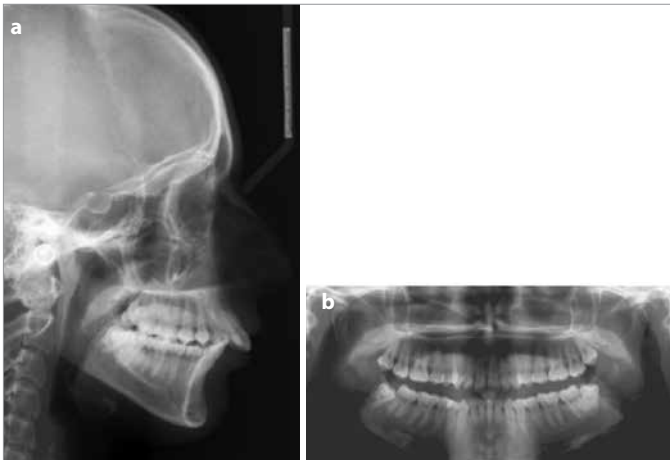


Figure 2. a, b. Pretreatment lateral cephalometric (a); panoramic radiographs (b)

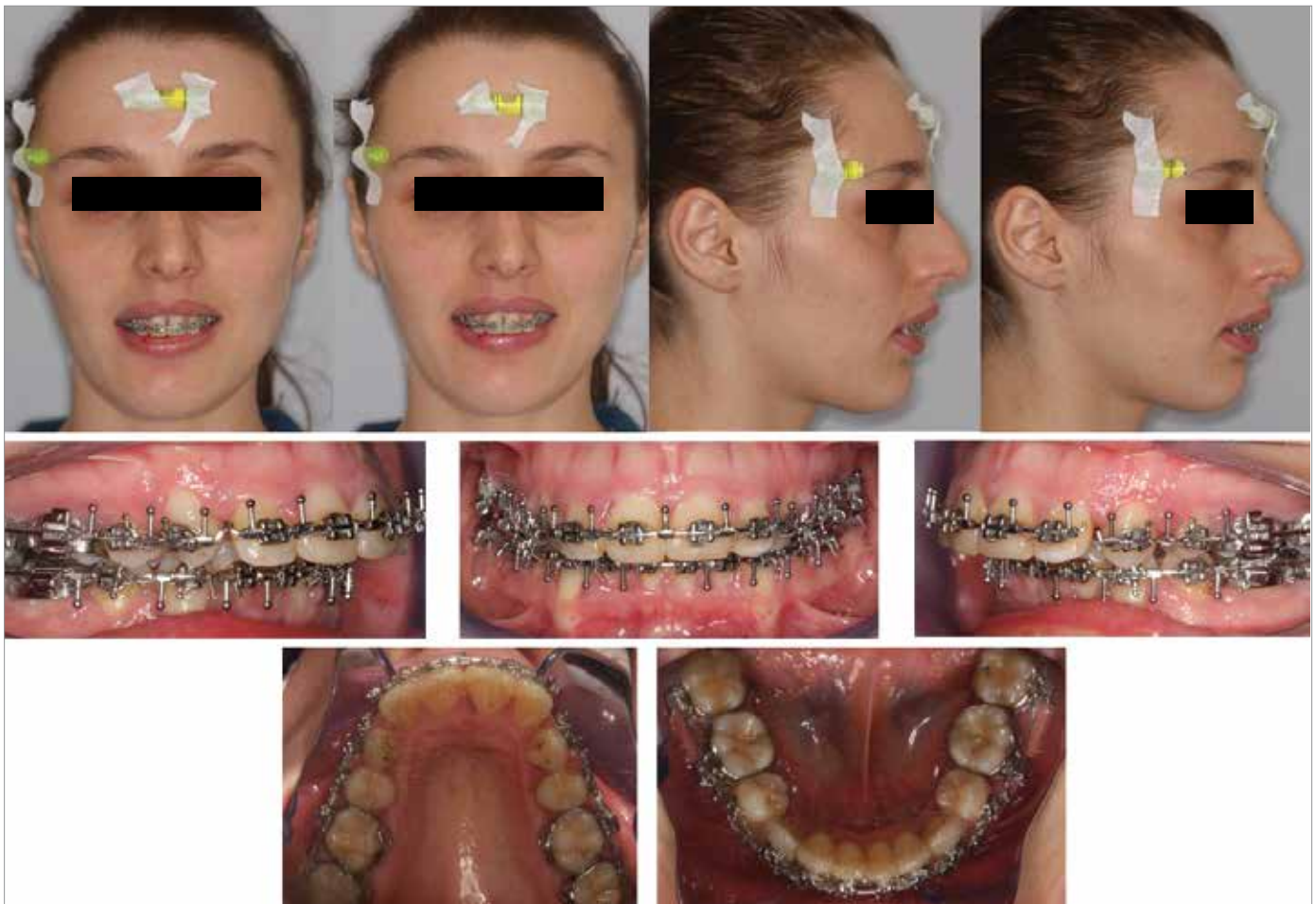

Figure 3. Preoperative extra- and intraoral photographs

arch and patient individually continued the IMF application, except during meals and jaw exercises, for 6 more weeks. The final splint was removed 8 weeks after the surgery, and a long-armed transpalatal arch was bonded. The diastemas distal to the laterals

were closed using the 0.019×0.025-in beta titanium alloy archwire with mushroom loops (Figure 7).

After debonding the braces, the upper and lower first bicuspid-to-bicuspid fixed lingual retainers were placed (Figure 8). A Hawley retainer for the upper jaw and a clear overlay retainer for the lower jaw were applied for approximately 1 year. The total treatment duration was 2 years.

After the orthodontic and orthognathic surgery, the skeletal and dental imbalance was corrected, and functional occlusion and dental and skeletal Class I relationship were achieved. A convex soft tissue profile, due to mandibular retrognathia, was corrected by mandibular advancement and counter-clockwise rotation. Ideal teeth and gingiva exposure were achieved by maxillary impaction. The patient had 2-mm overjet and 2.5-mm overbite. The lower dental midline was corrected and became coincident with the upper and facial midline Figure 6, 8, 9 (Table 1).

One-year after the treatment, a clinical and cephalometric analysis revealed that the skeletal and dental statuses were preserved Figure 10, 11 (Table 1).

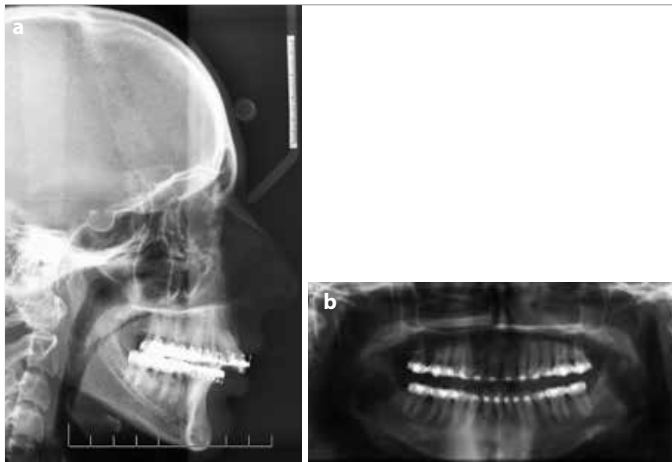


Figure 4. a, b. Preoperative lateral cephalometric (a); panoramic radiographs (b)

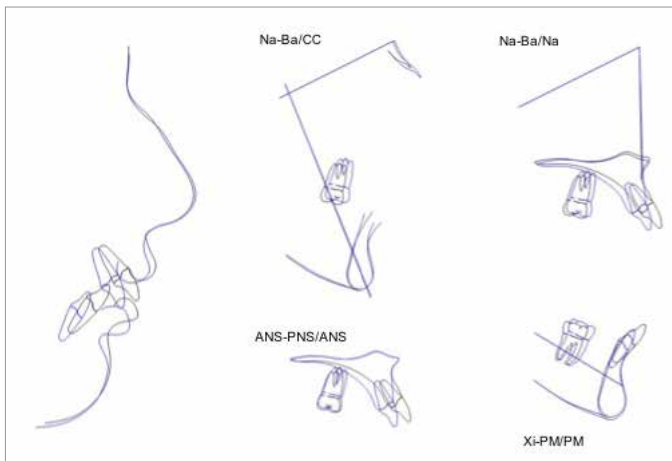


Figure 5. Initial and preoperative lateral cephalometric superimpositions Black: initial; blue: preoperative

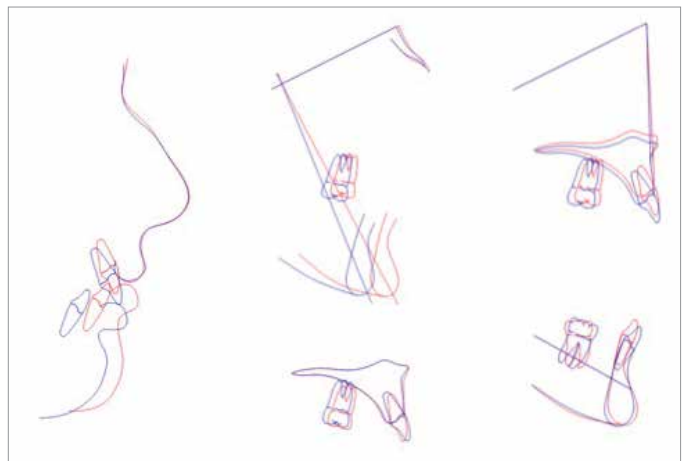


Figure 6. Preoperative and postoperative lateral cephalometric superimpositions Blue: preoperative; red: postoperative

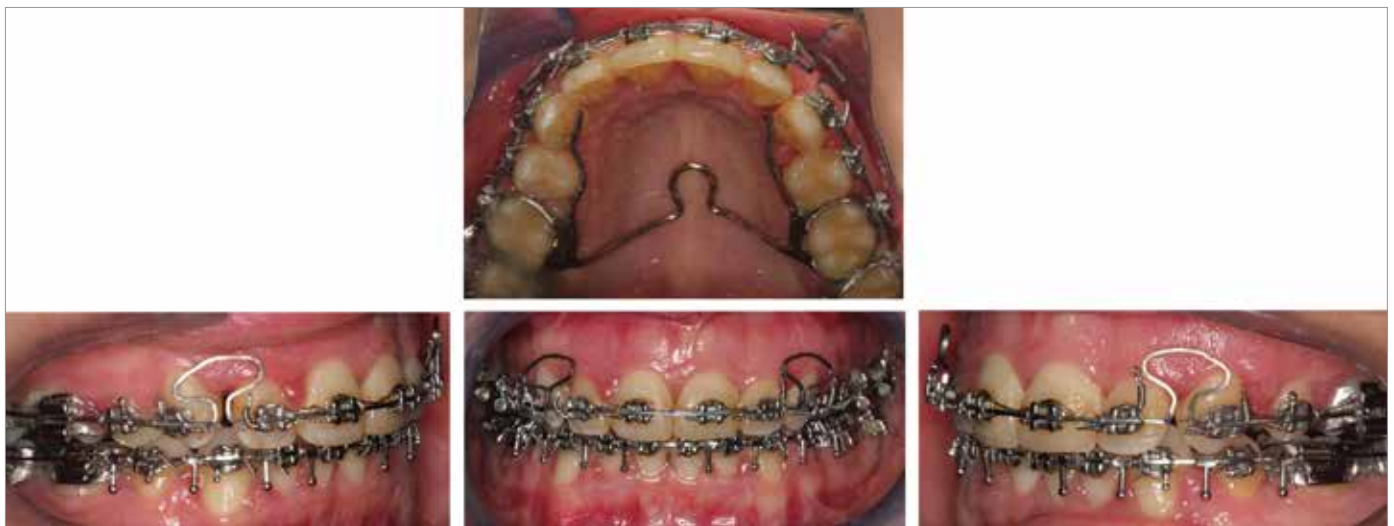

Figure 7. Postoperatively 3 months, space closure with 0.019 × 0.025-in beta titanium alloy archwire with mushroom loops

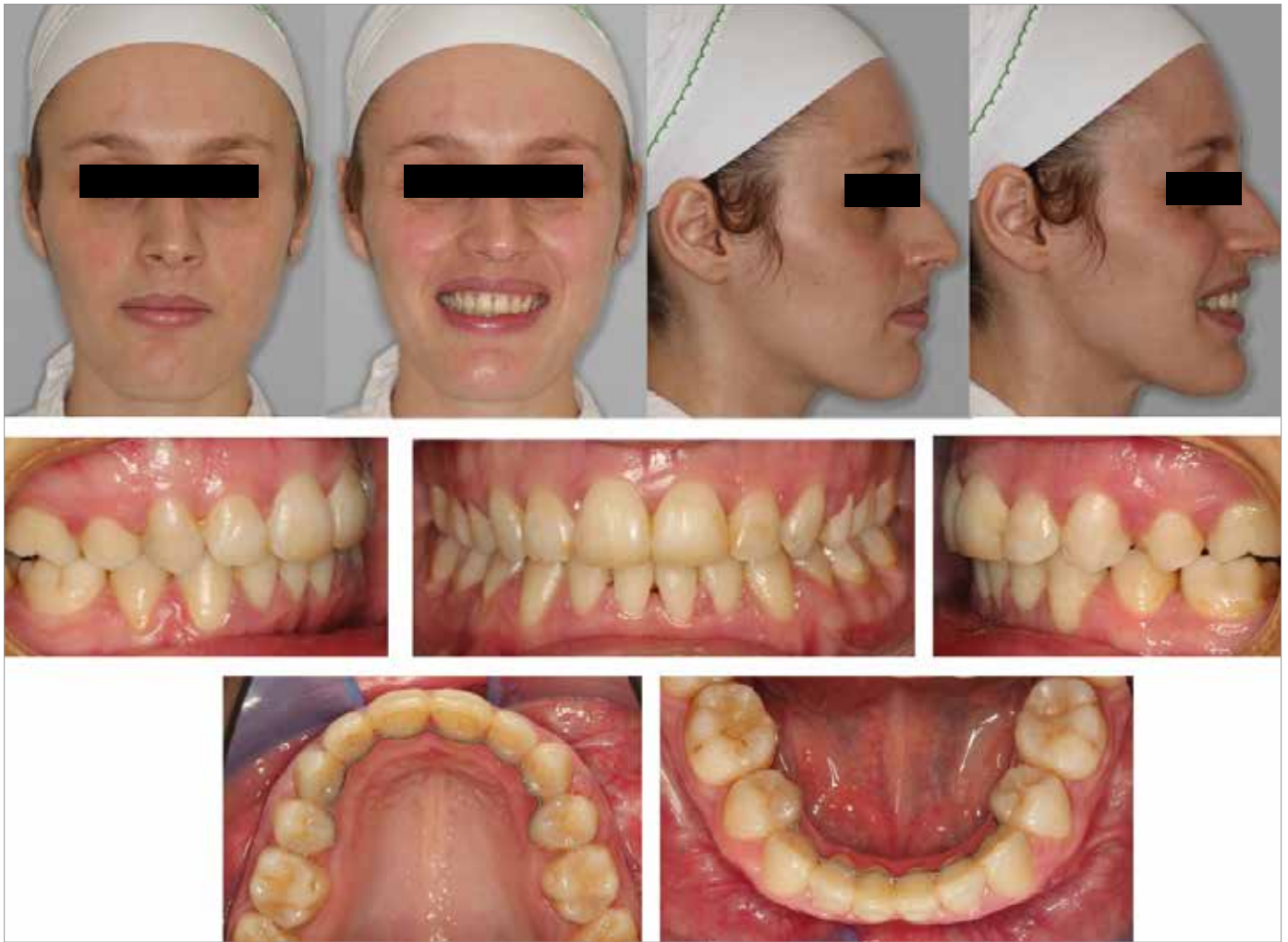

Figure 8. Post-treatment extra- and intraoral photographs

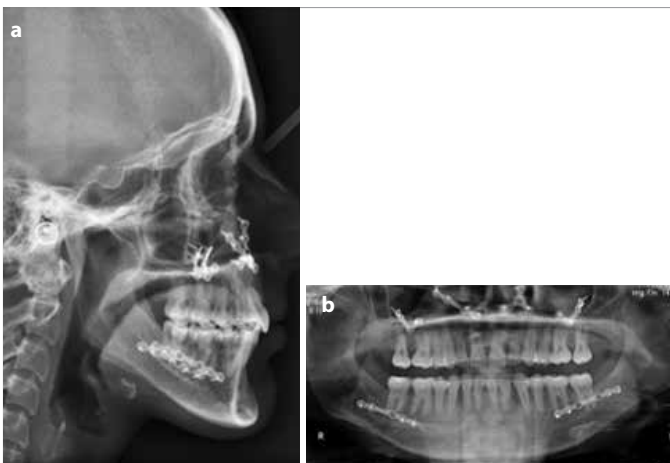


Figure 9. a, b. Post-treatment lateral cephalometric (a); panoramic radiographs (b)

CONCLUSION

Adult patients with skeletal Class II malocclusion can be treated using orthodontic (camouflage) or combined orthodontic-orthognathic surgery procedures. As Class II orthodontic camouflage treatments, the following can be performed: (1) for normalization

of increased overjet, upper first premolar extraction and upper incisors retraction and/or lower incisors protraction; (2) to correct Class II molar relationship, lower second premolars extraction; (3) maxillary arch distalization with miniscrews; and (4) Class II elastics with/without extractions (8-15). Upper incisor retraction with maximum anchorage to reduce the increased overjet causes the flattening of the nasolabial angle, straightening of lips profile, and emphasizing of the nose (3, 4, 8, 12-14). A significant improvement in the soft tissue profile is not possible because the dental movement limits the effectiveness of camouflage treatment; in some cases, the situation may worsen. Because the camouflage treatment is limited by tooth movement, there will not be a pronounced improvement in the soft tissue profile, and it may also worsen in some cases. Besides, when attempting to fit the dental structures to the abnormal skeletal bases, the teeth move away from their ideal position within the jaw, resulting in stability and health problems (3, 4, 8-10). When all these limitations and disadvantages of camouflage treatment are taken into account, the orthodontic-orthognathic surgery combined treatment will be the best option in severe skeletal discrepancy cases. Because the present case had severe skeletal discrepancies such as maxillary constriction, vertical overdevelopment, and mandibular retrognathia (SNB, 71.8°), we planned orthodontic-orthognathic surgery.

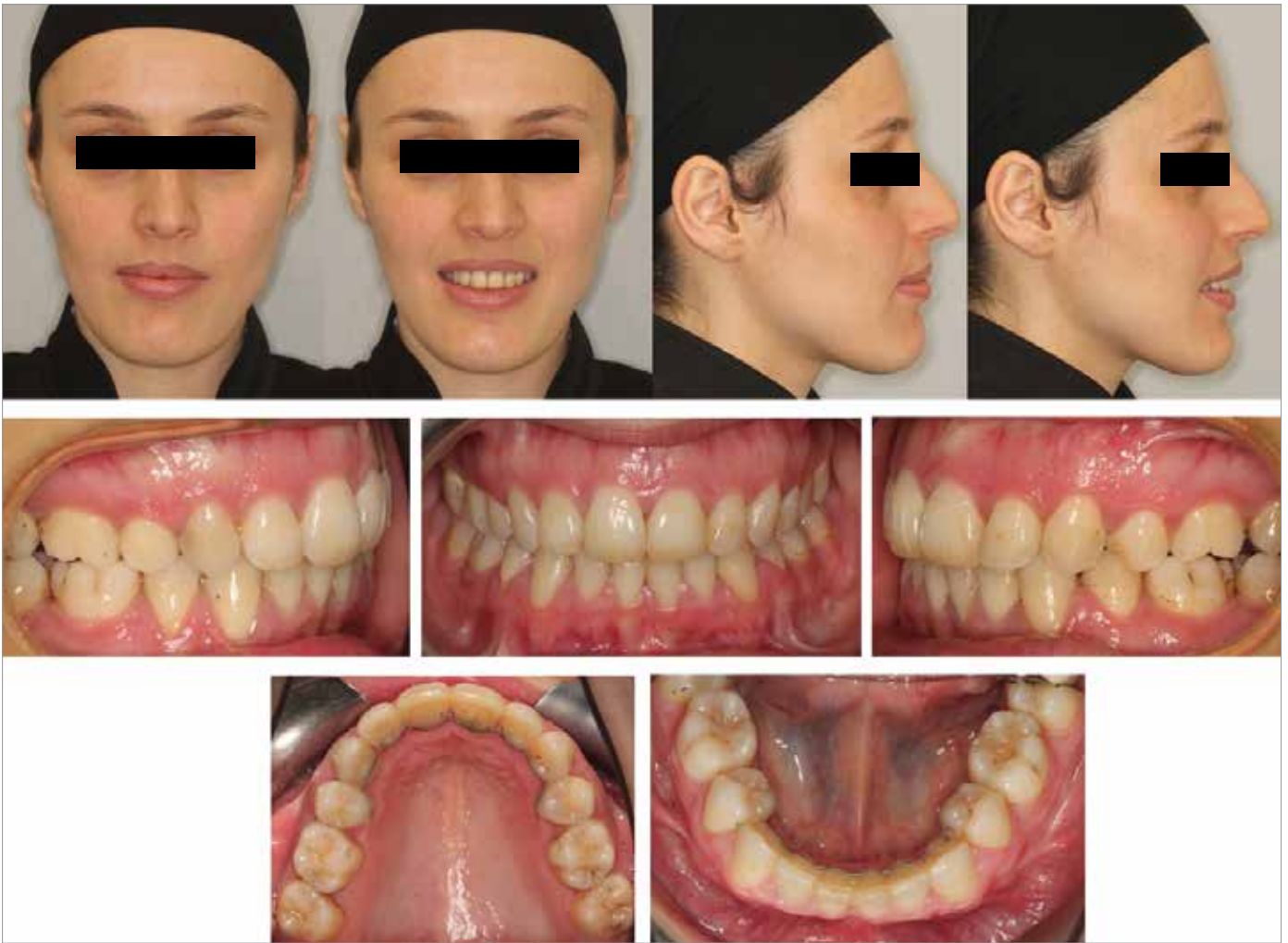

Figure 10. Extra- and intraoral photographs 1 year after treatment

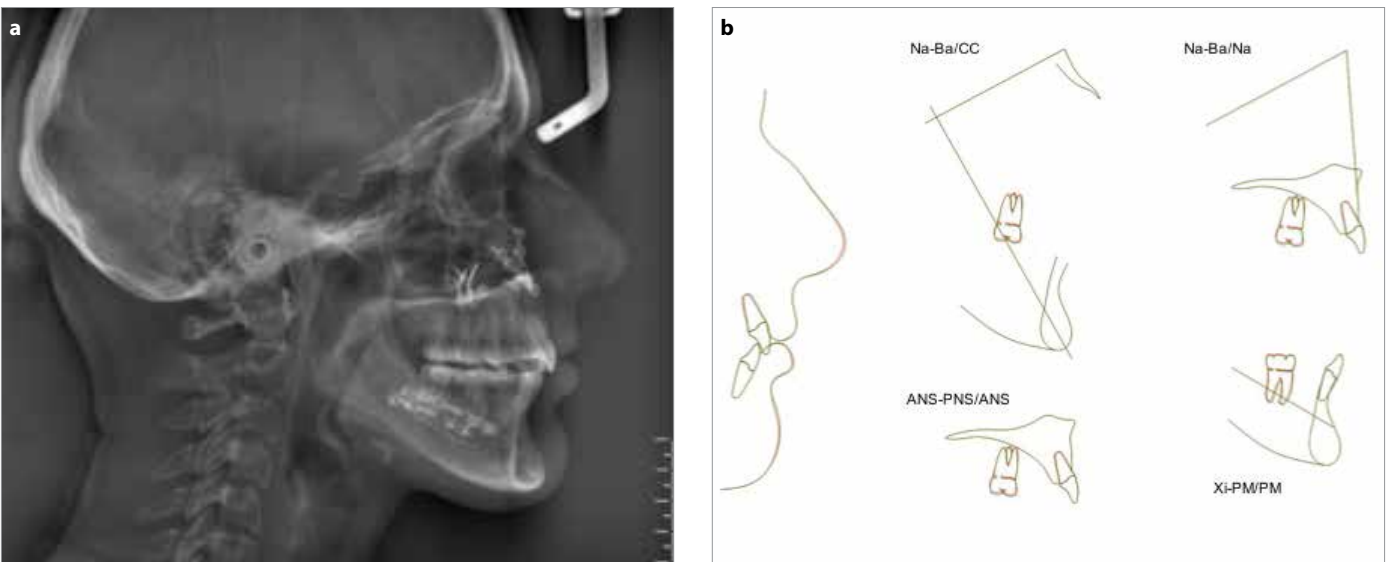


Figure 11. a, b. Lateral cephalometric radiograph 1 year after treatment Postoperative (a); 1-year post-retention lateral cephalometric superimpositions (b) Red: postoperative; green: 1-year post-retention

For the correction of the transversal maxillary constriction in adult patients, two options are commonly used, namely surgically-assisted rapid palatal expansion (SARPE) and (2) multisegmented Le Fort I osteotomy. The SARPE technique is mostly used in cases with severe transversal deficiencies (>7 mm) and no concomitant sagittal and vertical skeletal anomalies. In contrast, the multisegmented Le Fort I osteotomy procedure is preferred in cases with combined transversal constriction with anteroposterior and/or vertical discrepancies and a dual plane of occlusion (16-18). The present case required 4 mm of maxillary expansion and vertical repositioning to correct increased tooth and gingiva exposure both while smiling and in the natural rest position (maxillary vertical overdevelopment). Therefore, we preferred the multisegmented Le Fort I osteotomy technique.

In this case, during preoperative orthodontic treatment both relieving the crowding and obtaining the ideal incisor inclination, we decided to extract the upper and lower first premolars (3,4). Because we used continuous mechanics during the leveling and space closure period, we needed to cut the 0.019×0.025-in stainless steel upper archwire distal to the lateral incisors, and we waited for 3 months for dental relapse. After 3 months, we performed the surgery, and software (Dolphin Imaging and Management Solutions Chatsworth, California) was used for surgical planning. The patient underwent maxillary transversal, sagittal, and vertical repositioning using the multisegmented Le Fort I osteotomy and mandibular advancement with BSSO. Titanium plates were used for rigid fixation in surgery. IMF was performed 10 days postoperatively.

We extended the IMF application, except during meals and jaw exercises, to prevent relapse, which is mainly due to the maxillary expansion with the multisegmented Le Fort I osteotomy. Further, during the final splint removal, a long-armed transpalatal arch was immediately bonded. Post-treatment retention was done using the upper and lower bicuspid-to-bicuspid fixed lingual retainers, a Hawley retainer for the upper jaw, and a clear overlay retainer for the lower jaw. Skeletal and dental results were maintained at the post-treatment 1-year follow-up.

In a patient with severe skeletal Class II malocclusion with maxillary constriction, ideal results regarding function, esthetic, and airway can be achieved with orthodontic-orthognathic surgery using the multipiece Le Fort I osteotomy. Following dental decompensation with continuous mechanics, it is advisable to segment the archwire and wait for dental relapse. Preoperative dental relapse is necessary to obtain adequate skeletal correction and to distinguish the cause of postoperative relapse, whether skeletal or dental.

Informed Consent: Written informed consent was obtained from the patient who participated in this study.

Peer-review: Externally peer-reviewed.

Author Contributions: Concept - M.A.B., E.Ü., F.E., S.D.E.; Design - M.A.B., E.Ü., F.E., S.D.E.; Supervision - M.A.B., E.Ü., F.E., S.D.E.; Materials - M.A.B., E.Ü., S.D.E.; Data Collection and/or Processing - M.A.B., F.E., S.D.E.; Analysis and/or Interpretation - M.A.B., F.E., S.D.E.; Literature Search - M.A.B.; Writing Manuscript - M.A.B.; Critical Review - M.A.B., F.E.

Conflict of Interest: The authors have no conflict of interest to declare.

Financial Disclosure: The authors declared that this study has received no financial support.

REFERENCES

1. Proffit WR, Ackerman JL: Diagnosis and treatment planning, in Graber M, Vanarsdall RL. Jr (eds): Orthodontics: Current Principles and Treatment. St Louis, MO, Mosby, 1994.
2. Pancherz H. Dentofacial orthopedics or orthognathic surgery: is it a matter of age? Am J Orthod Dentofacial Orthop 2000; 117: 571-4. [\[CrossRef\]](#)
3. Proffit WR, Fields HR Jr, Sarver DM. Diagnosis and treatment planning in Contemporary Orthodontics: Orthodontic Treatment Planning: Limitations, Controversies, and Special Problems. 4th Edition. St Louis, MO, Mosby, 2007: p.302-307.
4. Arnett GW, McLaughlin RP. Facial and dental planning for orthodontists and oral surgeons. Mosby, An imprint of Elsevier Limited, 2004: p.261-3.
5. Lee KY, Park JH, Tai K, Chae JM. Treatment with Twin-block appliance followed by fixed appliance therapy in a growing Class II patient. Am J Orthod Dentofacial Orthop. 2016; 150(5): 847-63. [\[CrossRef\]](#)
6. Bacetti T, Franchi L, Toth LR, McNamara JA Jr. Treatment timing for Twin-block therapy. Am J Orthod Dentofacial Orthop 2000; 118: 159-70. [\[CrossRef\]](#)
7. Tomblyn T, Rogers M, Andrews L 2nd, Martin C, Tremont T, Gunel E, Ngan P. Cephalometric study of Class II Division I patients treated with an extended-duration, reinforced, banded Herbst appliance followed by fixed appliances. Am J Orthod Dentofacial Orthop 2016; 150: 818-30. [\[CrossRef\]](#)
8. Proffit WR, Sarver DM. Treatment in Adults in Contemporary Orthodontics: Combined Surgical and Orthodontic Treatment. 4th Edition. St Louis, MO, Mosby, 2007.p.689-93.
9. Tucker MR. Orthognathic surgery versus orthodontic camouflage in the treatment of mandibular deficiency. J Oral Maxillofac Surg 1995; 53: 572-8. [\[CrossRef\]](#)
10. Canıgür Bavbek N, Dinçer M. Sınır (Borderline) olgularda ortodontik kamufraj tedavisinin kararlaştırılmasına etki eden faktörler. J Dent Fac Atatürk Uni 2012: 44-51.
11. Tekale PD, Vakil KK, Vakil JK, Gore KA. Distalization of maxillary arch and correction of Class II with mini-implants: A report of two cases. Contemp Clin Dent 2015; 6: 226-32. [\[CrossRef\]](#)
12. Kinzinger G, Frye L, Diedrich P. Class II treatment in adults: comparing camouflage orthodontics, dentofacial orthopedics and orthognathic surgery-a cephalometric study to evaluate various therapeutic effects. J Orofac Orthop 2009; 70: 63-91. [\[CrossRef\]](#)
13. Demir A, Uysal T, Sari Z, Basciftci FA. Effects of camouflage treatment on dentofacial structures in Class II division 1 mandibular retrognathic patients. Eur J Orthod 2005: 524-31. [\[CrossRef\]](#)
14. Conley RS, Jernigman C. Soft tissue changes after upper premolar extraction in class II camouflage therapy. Angle Orthod 2006; 1: 59-65.
15. Mihalik CA, Proffit WR, Ceib Philips. Long-term follow-up of Class II adults treated with orthodontic camouflage: A comparison with orthognathic surgery outcomes. Am J Orthod Dentofacial Orthop 2003; 123: 266-78. [\[CrossRef\]](#)
16. Vandersea BA, Ruvo AT, Frost DE. Maxillary transverse deficiency: surgical alternatives to management. Oral Maxillofac Surg Clin North Am 2007; 19: 351-68. [\[CrossRef\]](#)
17. Bauer RE. III, Ochs MW. Maxillary orthognathic Surgery. Oral Maxillofac Surg Clin N Am 2014: 523-37.
18. Marchetti C, Pironi M, Bianchi A, Musci A. Surgically assisted rapid palatal expansion vs segmental Le Fort I osteotomy: Transverse stability over a 2-year period. J Craniomaxillofac Surg 2009; 37: 74-8. [\[CrossRef\]](#)